

## 3-D Imaging Techniques Transform Cardiac Catheterization



**The field of cardiac catheterization** has benefited significantly from the advent of two technologies that create 3-D images. The techniques — rotational angiography and the fusion of X-ray and MRI/CTA — are changing the way catheterizations are performed on patients with cardiovascular disease.

These state-of-the-art imaging techniques facilitate catheter-based minimally invasive interventions on patients who previously would have required surgery, thus decreasing the hospital stay, time in intensive care, recovery time and the amount of pain suffered.

### **XMRI/CT fusion creates a detailed road map**

MRI and CT imaging have become powerful clinical tools to improve upon traditional X-ray and echocardiographic imaging. Today, patients with congenital and structural heart disease and vascular disease may undergo MRI or CT to build a 3-D model in advance of the procedure. However, these images have traditionally not been transferrable to the cardiac catheterization fluoroscopic imaging systems. While 3-D images were helpful, during the procedure cardiologists, radiologists and surgeons had to rely on traditional X-ray images.

### **3-D visualization provides “the best seat in the house”**

Access to 3-D imaging during catheterization limits complications and has the potential to reduce radiation exposure, says Jamil Aboulhosn, M.D., assistant professor of medicine and director of the Ahmanson/UCLA Congenital Heart Disease Center.

“It’s really helpful for people with challenging and complicated anatomy, such as cases where you have to place a stent in an area where you can’t miss by more than a millimeter, or where you have a vessel that loops toward you and then away from you,” he says. “In 2-D, it’s hard to imagine what that looks like.”

CT and MR images to build the 3-D model are initially acquired by the Cardiac Radiology team, who ensure the highest quality studies are available for successful fluoroscopic overlay.

Rotational angiography provides superior visualization based on X-rays taken at a rate of a dozen per second.

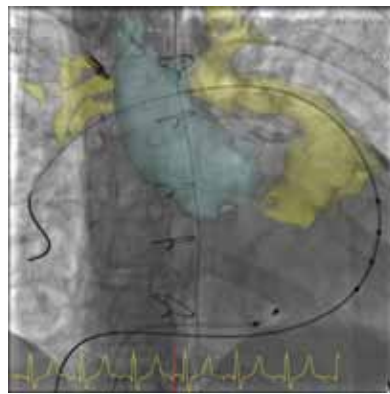
“I can pick the perfect angle to best see the narrowing and program my cameras to go to that angle,” Dr. Aboulhosn says. “It allows me to pick the best seat in the house to see the action I really care about.”

XMRI/CT fusion has changed that by allowing UCLA clinicians to use innovative software, installed on catheterization lab workstations, to overlay the 3-D MRI or CT image onto the active fluoroscopy screen during the procedure. With this fusion of images, clinicians can isolate areas of the anatomy critical to the procedure and follow a road map that changes in real time and space as the table position and camera position are adjusted. The technology is most useful in complicated procedures such as the replacement of a dysfunctional valve or repair of an aortic aneurysm.

XMRI/CT fusion, which is also called fluoroscopy-MR/CT overlay, can be synchronized with heart beat and respiration. The technique, suited to both adult and pediatric patients, is being used for transcatheter pulmonary valve replacement, stenting coarctation of the aorta and vascular angioplasty and stenting.

### Rotational angiography provides new information

3-D angiography, also known as rotational angiography, further advances catheterization through enhanced imaging. In contrast to the images produced by traditional 2-D angiography, the rotational X-ray travels 210 degrees around the patient during the injection of contrast to generate data at various angles. The ensuing 3-D model can provide enhanced diagnostic accuracy and assist in decision-making during the procedure, such as the choice of stent size or balloon required.



*3-D angiography fluoroscopic overlay used to guide transcatheter pulmonary valve replacement.*

Moreover, rotational angiography aids clinicians by revealing the relationship between adjacent structures. This is essential in procedures carrying the risk of serious complications, such as some types of valve replacement. Using 3-D rotational angiography, the clinician can safely place a percutaneous pulmonary valve without compressing the coronary artery, a complication with serious ramifications. The improved visualization of the structure from all angles provides assurances of safety and efficacy.

Rotational angiography can be used for patients with vascular disease, including those with stroke or heart attack diagnoses, peripheral vascular disease, narrowing of the renal arteries and structural heart disease.

### UCLA is pioneering 3-D imaging in cardiac catheterization

As one of the largest facilities of its kind, the Ahmanson/UCLA Adult Congenital Heart Disease Center has emerged as a leader in the development of 3-D imaging in cardiac catheterization. The center provides services to the growing number of patients with congenital heart disease who reach adulthood. The center's staff is collecting data on the growing uses of 3-D imaging to improve the application of the technology to areas where it's most useful.

## Participating Physicians

### **Jamil Aboulhosn, M.D.**

Associate Professor of Medicine

Director of the Ahmanson/UCLA Congenital Heart Disease Center

### **Daniel Levi, M.D.**

Associate Professor  
Pediatric Cardiology

### **John Moriarty, M.D.**

Assistant Clinical Professor  
Radiological Sciences

## Contact Information

(310) 825-9011 Appointments  
and Information

[achdc@mednet.ucla.edu](mailto:achdc@mednet.ucla.edu)