

Highly Advanced Imaging Contributes to World Class Brain Tumor Care

Benjamin M. Ellingson, PhD
Professor of Radiology and Psychiatry
Director, UCLA Brain Tumor Imaging Laboratory (BTIL)
Department of Radiological Sciences
David Geffen School of Medicine at UCLA



For some types of brain tumor — particularly high-grade malignancies like glioblastoma — treatment decisions must be made quickly due to the aggressive nature of the disease. Choosing to begin, continue or change treatments are decisions best made with timely input from a variety of specialists. At UCLA, an integrated, interdisciplinary team works together to produce the best possible treatment outcomes.

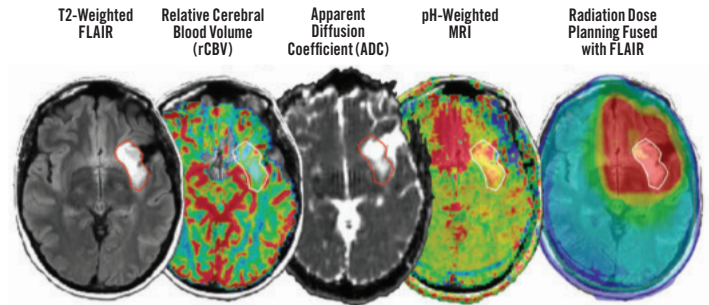
“When treating most types of cancer, you can surgically remove various aspects of the tumor to see how the treatment has affected the tumor tissue,” explains Benjamin M. Ellingson, PhD, professor of radiology and psychiatry and director of the UCLA Brain Tumor Imaging Laboratory. “With brain tumors, we rely heavily on imaging to provide information on whether a particular treatment is working.”

At UCLA, radiologists and imaging scientists participate at every stage of brain cancer patients’ care. Beginning with initial entry into the system — including Emergency Department visits when patients present with acute symptoms — UCLA radiologists and scientists help manage patients through diagnosis and staging, presurgical and radiation oncology target planning, postsurgical assessment and therapeutic response to radiation, and routine follow-up imaging for all treatment modalities.

UCLA has developed a number of new imaging modalities in the course of researching and treating brain tumors. Leading-edge imaging technologies being used at UCLA to help our interdisciplinary team make better-informed treatment recommendations include pH-weighted MRI and oxygen-enhanced MRI.

Both of these imaging technologies exploit the unusual metabolism that some brain tumors exhibit in favoring glycolysis for energy production. The pH-weighted MRI technique detects the concentration of lactic acid, a byproduct of glycolytic metabolism. UCLA radiologists are able to quantify the lactic acid buildup to track response to a variety of brain cancer treatments. “different genetic or molecular subtypes of tumors have different metabolic signatures,” states Dr. Ellingson. “We can pick up these patterns with a short, seven-minute scan. It’s very clinically feasible and has been integrated into UCLA’s standard of care for appropriate patients.”

Oxygen-enhanced MRI can distinguish between normal tissue, which uses oxygen to create energy, and some types of malignancies that use anaerobic glycolysis whether oxygen is available or not. Images made while the patient breathes different concentrations of oxygen distinguish tissue metabolizing glucose with oxygen from tissue relying solely on anaerobic glycolysis. “Some types of malignancies will use only anaerobic glycolysis. Others, such as slow-growing IDH mutant tumors, prefer oxidative phosphorylation,” explains Dr. Ellingson.



Advanced brain imaging available at UCLA (first four images from left), combine metabolic and physiologic information to inform treatment decisions, including radiation treatment strategy (right image).

Other highly advanced imaging technologies available at UCLA include 18F-FDOPA PET, which uses an amino acid imaging tracer, and 18F Clofarabine PET, which can be used to monitor immunotherapies. Another imaging technology that UCLA is bringing online is sodium MRI. It will be used to examine brain tumor electrophysiology as well as other biological processes.

In addition to offering these and other highly advanced imaging techniques available at few, if any, other centers, UCLA Radiology has more widely implemented the advanced imaging techniques that may be available, but are not yet routine, at other academic centers. Imaging modalities like perfusion and diffusion MRI are offered at a number of centers, but at UCLA they are integrated into routine follow-up care throughout our clinical enterprise. “With these technologies, we’re able to look at vascularity within a tumor — angiogenesis and blood volume — and track whether they are changing over time as tumors grow or respond to therapy,” states Dr. Ellingson.

Finally, UCLA Radiology has spearheaded an international movement to have a standardized core MRI imaging protocol for brain tumors. All UCLA brain tumor patients get the same anatomical imaging protocol at all time-points throughout their care independent of where within the UCLA system they are seen. This same type of standardized imaging has since been mandated by the National Cancer Institute and Food and Drug Administration for all clinical trials, with many leading academic institutions adopting UCLA’s existing standards. This will prove important in brain cancer research, where standardized imaging will allow relatively modest numbers of patients at each institution to be combined into larger, more meaningful clinical trials. 