

Radiologists Collaborate in Caring for Patients with Liver Disease

David Lu, MD

Professor of Radiology

Chief of Cross Sectional Interventional Radiology

Director of CT, High Intensity Focused Ultrasound

Program and UCLA Liver Tumor Ablation Program

Department of Radiological Sciences

David Geffen School of Medicine at UCLA



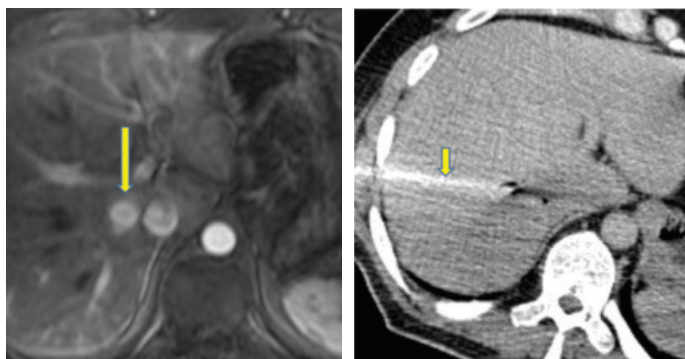
For patients with liver cancer and other liver disease, “it’s very important to identify information that helps determine the health of the liver, and to identify tumors and anatomic features that can affect surgical technique,” states David Lu, MD, professor of radiology and director of the UCLA Liver Tumor Ablation Program.

The multidisciplinary treatment teams at the Pflieger-UCLA Liver Cancer Center and Dumont-UCLA Liver Transplantation Program rely on experts in diagnostic liver imaging to help determine and plan treatments, as well as interventional specialists to help carry them out. UCLA was among the first centers in the U.S. to establish integrated, multidisciplinary programs for liver cancer and liver transplantation.

At UCLA, patients with hepatocellular carcinoma or metastatic liver cancer are seen in a multidisciplinary clinic, where they have access to subspecialty physicians from all relevant specialties in a single, convenient visit, including hepatobiliary surgeons, hepatologists, liver oncologists and diagnostic and interventional hepatobiliary radiologists. Patients’ treatment plans can be determined during that initial clinic visit with input from all specialists.

Re-interpreting Outside Scans

Most liver disease patients seen at UCLA and are referred from outside physicians and have had imaging studies performed at other clinics. UCLA hepatobiliary radiologists re-evaluate the available imaging to help determine the optimal treatment plan. “Identifying and staging tumors accurately in the liver is quite challenging and it’s not uncommon that lesions previously identified as cancer turn out in fact to not be cancerous at all,” states Dr. Lu. “Also, lesions that initially seemed to be suitable for liver resection or liver transplant, sometimes turn out after review



Patient with history of renal cell carcinoma referred to the Liver Cancer Center for definitive management of a reported single hypervascular metastasis to the liver (long arrow, on arterial phase MRI). On review of imaging the lesion diagnosis was changed to most likely focal nodular hyperplasia, a benign condition. Subsequent biopsy was performed by a hepatobiliary interventional oncologist (short arrow show biopsy needle under CT), and the benign diagnosis was confirmed. Patient ended up not needing any invasive treatment or chemotherapy.

to be at more advanced stages, making alternate therapeutic plans more appropriate.”

When further imaging studies are needed, it is important that the most current scanning protocols — some of which were developed at UCLA — are followed. “Even if a facility has the most current CT and MRI equipment, if they’re not being put to use with the most optimized scanning methods, the images are not going to produce the right results,” states Dr. Lu. Many tumors can be accurately identified and staged only with carefully coordinated timing between the delivery of contrast and the imaging scans. Strict scanning protocols at UCLA help ensure optimal scan quality.

Interventional Oncology Treatments as a Bridge to Transplantation

Patients with liver cancer awaiting a donor organ for transplantation — a wait that is likely to be at least several months if not multiple years — are at risk for developing tumor growth that will reduce the effectiveness of liver transplant, and therefore jeopardize their status on the waiting list. At UCLA, these tumors are treated by interventional radiologists using minimally invasive thermal ablation or embolization techniques, and patients are carefully monitored for new tumor growth with continued treatment as necessary. In this manner, patient’s transplantation plans are kept on track. UCLA recently produced data showing that the integration of tumor ablation followed by transplantation produces very high 10-year survival rates in patients with early stage liver cancer.

Intraoperative Ultrasound and Ablation

In a unique interdisciplinary collaboration at UCLA, radiologists are joining surgeons in the operative room during surgery for liver cancer. After having mapped out the locations of lesions with preoperative imaging studies, radiologists use intraoperative ultrasound to locate the mapped lesions. “Many of these are deep lesions that cannot be seen superficially or felt with palpation,” explains Dr. Lu. In addition to locating the lesions, the intraoperative ultrasound enables radiologists to help surgeons determine the best way to safely resect deep lesions based on anatomic features of the patient’s liver.

In some instances, lesions deep in the liver cannot be safely resected. In these cases, the radiologist is able to use intraoperative ultrasound-guided ablation to destroy the lesions while minimizing the damage to surrounding tissue. 