

COVID's Role in Neurological Disease Remains Uncertain

Noriko Salamon, MD, PhD

Professor of Radiology
Vice Chair of Academic Affairs
Chief of Neuroradiology
Department of Radiological Sciences
David Geffen School of Medicine at UCLA



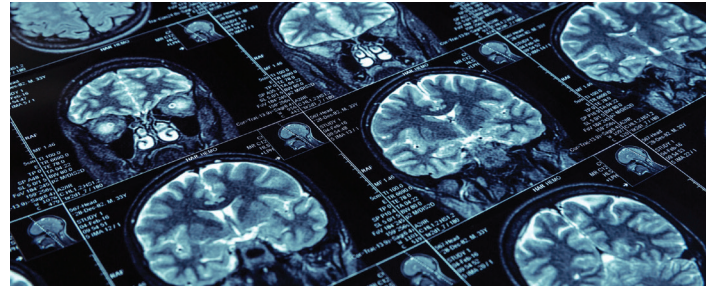
While the SARS-CoV-2 virus is known to primarily attack the lungs, there have been many reports of neurological manifestations, including encephalitis due to infection and occlusive and hemorrhagic stroke. Neurological complications of COVID-19 appear to correlate with the severity of the underlying COVID infection, with even younger patients suffering severe cases that produce neurological symptoms.

Published accounts from the Spring 2020 surge of COVID patients in New York suggested that in addition to neurological symptoms of headache, dizziness, myalgia, seizures, weakness and alterations of consciousness, COVID patients were suffering ischemic stroke (0.4 to 2.7 percent), intracranial hemorrhage (0.2 to 0.9 percent) and encephalopathy (0.04 to 0.2 percent) at higher rates than other patients.

Noriko Salamon, MD, PhD, professor of radiology and neuroradiology at the David Geffen School of Medicine at UCLA cautions, "I don't think we have enough evidence yet to reach conclusions about COVID's role in neurological conditions seen in some patients." She points out that severely ill COVID patients are often both immunocompromised and hypoxic. The presumed complications and sequelae of COVID may be less dependent on direct action of the SARS-CoV-2 virus and more a consequence of the poor health status of severely ill COVID patients. "Nothing can be identified at this point as typical about neurological disease in COVID patients," states Dr. Salamon. "COVID patients may exhibit some neurological symptoms because of the hypoxic environment created by COVID's well-documented effect on pulmonary function."

While pointing out that many of the most seriously ill patients cannot undergo imaging for their neurological symptoms because their hypoxia is not adequately managed, Dr. Salamon says that the majority of COVID patients seen at UCLA who display neurological symptoms indicative of stroke are in fact negative for stroke on MRI. "Probably less than 30 percent of these patients have abnormal brain scans," she says. "The majority of these cases have an unremarkable MRI, and the things that we do see on MRI are often likely to be conditions that predate the patient's COVID infection." Dr. Salamon adds that neurological symptoms in ICU patients where MRI fails to reveal abnormalities in the brain are not atypical for patients who are very ill with non-COVID conditions.

Despite her caution in attributing neurological conditions directly to COVID, Dr. Salamon points to recent UCLA research published in the journal *Stroke* that supports the idea that endothelial cells lining blood vessels in the brain are susceptible to the SARS-CoV-2 virus. Using vascular imaging — including cell wall molecular analysis, the team of researchers determined that in COVID patients, expression of the ACE2 (angiotensin-converting enzyme 2) receptor increased with vessel size and flow rate. If this is related to viral preferential attachment to vessel walls, it could help account for the atypical areas of vessel occlusion noted in some COVID patients.



While typical locations for atherosclerosis are bifurcation points where turbulent blood flow is associated with stenosis, vessel occlusion in COVID patients is often seen in more distal, high-flow areas.

As for COVID patients diagnosed with encephalitis due to neurological infection, Dr. Salamon warns against assuming that the SARS-CoV-2 virus is the infecting agent. COVID patients are immunosuppressed and are susceptible to any number of viral, bacterial and fungal infections. "While it is difficult to say that COVID is the direct cause of a neurological infection, it's very easy to say that COVID creates a state of immunosuppression that can lead to these infections," explains Dr. Salamon. In her experience, imaging studies of COVID patients who have neurological infections show the same distribution of the infection as do imaging studies for other viral diseases, such as Japanese encephalitis, West Nile virus, Epstein-Barr and herpes encephalitis. Dr. Salamon states, "The overlapping veno-occlusive, hypercoagulable status of COVID patients gives infection a good environment in which to thrive."

Starting with the first reports of COVID's neurological manifestations that came out of the early surge in New York, Dr. Salamon and her colleagues at UCLA have been especially vigilant for neurological disease among the COVID patients that they evaluate. "Early experience with COVID patients and preliminary analysis led to a popular notion that COVID causes stroke in young people and COVID causes infections — as if COVID is a bug that can initiate certain types of infections or certain types of stroke," explains Dr. Salamon. "I don't have this impression from seeing COVID patients at UCLA." She feels that there isn't currently sufficient evidence to conclude that the SARS-CoV-2 virus causes either infection or cerebrovascular disease directly. But because COVID causes some patients to become devastatingly ill, it can create an environment in which neurological disease can flourish. Neuroradiologists will continue to play an important role in helping to care for these seriously ill patients and are often crucial to their management and recovery from SARS-CoV-2 infection. 