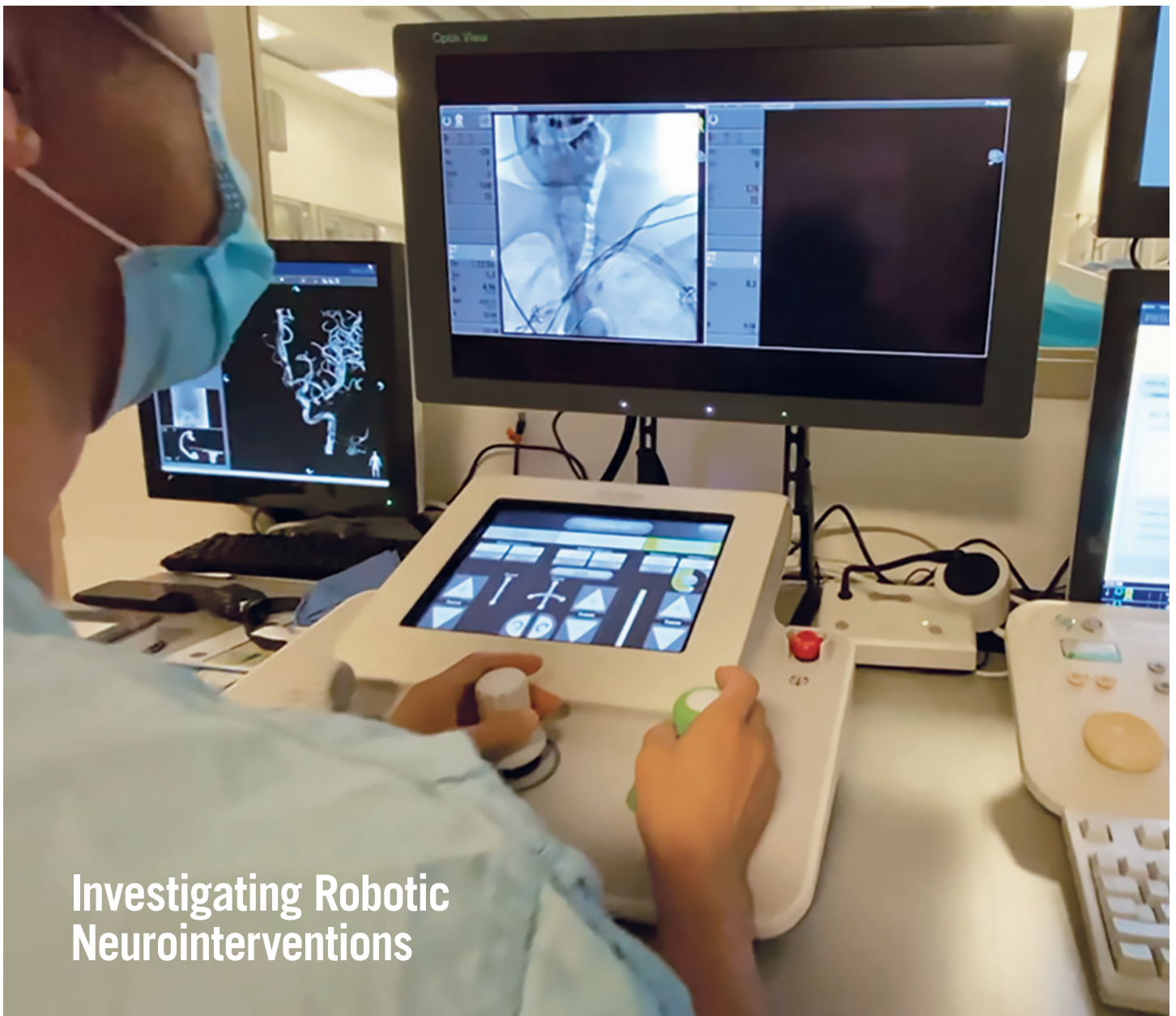

# UCLA Radiology

NEWSLETTER OF THE DEPARTMENT OF RADIOLOGICAL SCIENCES

WINTER 2021



## Investigating Robotic Neurointerventions

IN THIS ISSUE | CHAIR'S MESSAGE [P. 2](#) | MRI CAN IMPROVE PROSTATE CANCER SCREENING [P. 3](#) | INVESTIGATING ROBOTIC NEUROINTERVENTIONS [P. 4](#) | USING ARTIFICIAL INTELLIGENCE TO INTERPRET SCREENING MAMMOGRAMS [P. 6](#) | PHOTON COUNTING DETECTOR COMPUTED TOMOGRAPHY [P. 8](#)

# Chair's Message



## Dieter Enzmann, MD

Distinguished Professor of Radiology  
Leo G. Rigler Chair  
Executive Medical Director,  
UCLA Health  
Department of Radiological Sciences  
David Geffen School of Medicine  
at UCLA


As the severity of the COVID crisis recedes, we can begin to allow ourselves a glimpse into the next, reshaped chapter of radiology. Some adaptations formulated during the crisis like hybrid work scheduling will remain permanent. We will revisit and resume progress on previous trends. A societal observation is that crises can accelerate trends already underway. Teleradiology and artificial intelligence (AI) trends show this. COVID shined Klieg lights on urgent health disparities which will be more diligently measured and more directly corrected. Disparities in radiology appear in even common exams such as a differential use of prostate MR imaging in minority patients.

A salient trend in the economy, in healthcare and now in radiology, is consolidation, the merging of similar businesses. In crises, size does matter and many small radiology practices struggled to weather sudden, sometimes severe decreases in patient volume. To understand competitive environments, I find this quote from evolutionary biology illuminating, “Any organism’s success depends on the behavior of its contemporaries. For most traits or behaviors there is likely no optimal design or strategy, only contingent ones.”<sup>1</sup> Contemporaries have and continue to grow convincingly in size, but that needs to be accompanied by attaining economies of scale and scope. Future radiology practices will reside in large, non-profit and for-profit organizations and may either become an outside “supplier” or be integrated internally in a healthcare system. As suppliers there is possible exposure to the vicissitudes of that market position, although building a strong brand may mitigate some of that risk. Radiology practices embedded in a large healthcare system must become integral to the dominant system culture, provide service levels consonant with that culture, and augment the system’s brand name. “Supplier” radiology practices must still have a culture compatible with that of the larger system. In both scenarios, imaging services will ride the teleradiology trend.

Despite initiatives to limit overuse of imaging, its apparent value continues to fuel growth. Imaging is becoming a component of surgical procedures, especially when robots are incorporated. This trend has driven construction of “hybrid ORs” that have features similar to classic radiology suites. Imaging-based diagnostic procedures can achieve more accurate diagnosis as illustrated in this newsletter by MR-guided prostate biopsies. The imaging-robotics combination trend extends beyond radiology to pulmonologists for example. Wider

adoption of image-guided treatment (IgRx) means traditional interventional radiology (IR) needs to continue to innovate and differentiate from competition (see above quote). Many innovations are recombinations or cross-pollination of well-known IR techniques as in geniculate artery embolization for osteoarthritic knee pain, or prostate artery embolization for benign prostate hypertrophy. Some address non-exotic, common medical conditions like thyroid ablation.

Radiology cannot forget to improve basic imaging technology. Established CT imaging technology will experience a new learning curve as it acquires multi-energy imaging capability. Photon counting is one technology described in this newsletter that offers more precise discrimination of x-ray photons to generate “iodine” images, Zeffective imaging, low monoenergy images, and virtual non-contrast images. The potential value of these new CT features could be more accurate diagnosis, diagnostic time savings, and overall reduced patient radiation.

Charles Handy’s quote can be insightful, “The world keeps changing. It is one of the paradoxes of success that the things and the ways which got you where you are, are seldom those that keep you there.”<sup>2</sup> In a rapidly changing world of competing large healthcare networks and of the repositories of knowledge (think AI), radiology will need to find new ways to occupy a central medical communication role as well as expanding its treatment roles via IgRx. Uncomfortable change will be necessary, otherwise we may fall victim to Pablo Picasso’s admonition, “Success is dangerous. One begins to copy oneself, and to copy oneself is more dangerous than to copy others. It leads to sterility.” Radiology must innovate rather than rely on and copy historical strengths. 

<sup>1</sup> Chris Colby, *Introduction to Evolutionary Biology*

<sup>2</sup> Charles Handy, *The Age of Paradox*

# MRI Can Improve Prostate Cancer Screening by Adding Individualized Tumor Information

**Steven S. Raman, MD, FSAR, FSIR**  
Professor of Radiology, Urology and Surgery  
Director, UCLA Prostate MRI and Interventional Program  
Director, UCLA Abdominal Imaging Fellowship  
Department of Radiological Sciences  
David Geffen School of Medicine at UCLA



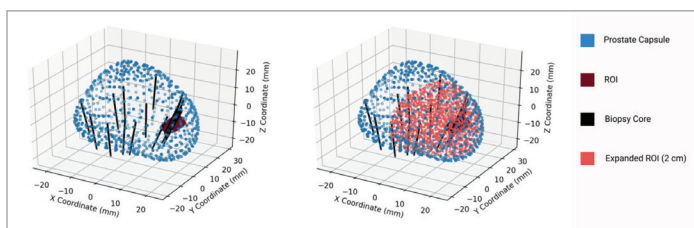
Prostate cancer presents management challenges that make it unique among solid organ cancers. “Unlike other cancers, for men it’s not a matter of ‘if’ you get prostate cancer, it’s a matter of ‘when’ you get prostate cancer,” explains Steven Raman, MD, professor of radiology and director of the UCLA Prostate Imaging and Image Guided Treatment Program. “Over 80 percent of men over the age of 80 have some prostate cancer, which is not true of other cancers.” The key to managing the disease is to know what type of prostate cancer an individual man has and how aggressively it is likely to behave, which helps determine how aggressively it should be treated. Non-aggressive prostate cancers could be managed conservatively with active surveillance and MRI, but usually are left untreated to avoid the morbidity of sexual and urinary dysfunction associated with prostate cancer treatments.

Despite the usefulness of individualized information, the standard of care for prostate cancer screening has been uniform. Men typically present with an elevated blood PSA (prostate specific antigen) level (> 4) or the presence of a nodule on digital rectal examination, both of which are nonspecific and do not differentiate between aggressive and non-aggressive prostate cancer subtypes. Typically this is followed by a transrectal ultrasound (TRUS) guided systematic biopsy of the prostate gland to try to detect prostate cancer, which can then be categorized according to the Gleason grading system. However, this fails to accurately estimate individual cancer risk in up to 50 percent of patients.

“Since the early 1990s, men have been getting tested for PSA, which is a good test but not a great test because it leads to overdiagnosis,” explains Dr. Raman. “It does pick up the majority of men with prostate cancer, however it doesn’t discriminate between aggressive and non-aggressive subtypes.” The widespread use of PSA resulted in a significant decrease in prostate cancer mortality in the 1990s, but it came at the cost of very widespread sexual and urinary morbidity and overtreatment for many other men.

This may be in the process of changing as MRI (magnetic resonance imaging) is proving to be useful in identifying the most aggressive prostate cancer tumors for biopsy and — importantly — in returning a negative result when non-aggressive tumors don’t present immediate threats to men’s health.

“UCLA data shows that using MRI, we can detect 80 to 90 percent of the aggressive disease (Gleason score > 7) while detecting less than 50 percent of the non-aggressive disease,” states Dr. Raman. “For the last 11 to 12 years, we’ve also pioneered the use of MRI



A landmark study by Drs. Corey Arnold and Steven Raman (*Raman et al. J Urol 2021; 206(3): 595-603*) of detailed 3D biopsy analysis of 16,459 biopsy cores in 1,000 patients showed that over 97 percent of clinically significant prostate cancers (red dots in figure above) were within 2 cm of the MRI target (brown spot), further validating the technique and decreasing the need for extensive systematic biopsies, which add risk of bleeding, infection and pain.

targeted biopsy — biopsying the most aggressive disease we see under MRI using a variety of fusion imaging techniques as well as direct MRI-guided biopsy in the MR scanner. Our most recent analysis (Fig. 1) shows that 97 percent of clinically significant prostate cancers were within 2 cm of the MRI target, requiring less extensive prostate biopsy samples.

A recent population based study in Sweden enrolled 12,750 men to compare standard prostate cancer screening to a screening program that adds the use of MRI in detecting clinically significant disease. Men with PSA scores of 3 and higher (1,532 men met the study criteria) were randomized to receive either standard systematic TRUS biopsy or an MRI followed by a targeted TRUS biopsy and a standard systematic biopsy if the imaging indicated the presence of aggressive prostate cancer.

Clinically significant prostate cancer — defined as a Gleason score of 7 or higher following histological examination of the biopsy tissue — was detected in 21 percent of those in the MRI arm of the study, compared to 18 percent for those in the standard-of-care arm. In addition, only four percent of the men in the MRI arm detected as positive for prostate cancer but proved to have clinically insignificant disease. In the standard-of-care arm, 12 percent of those detected positive proved clinically insignificant for prostate cancer. “This study mirrors our long experience at UCLA, initially published 10 years ago,” says Dr. Raman. “MRI is very good at detecting significant prostate cancer while not detecting insignificant prostate cancer.”

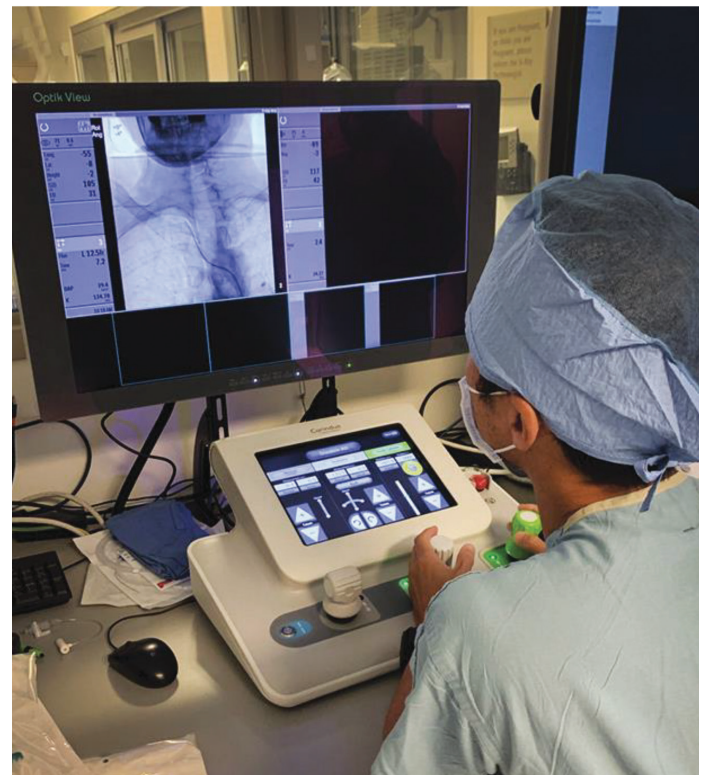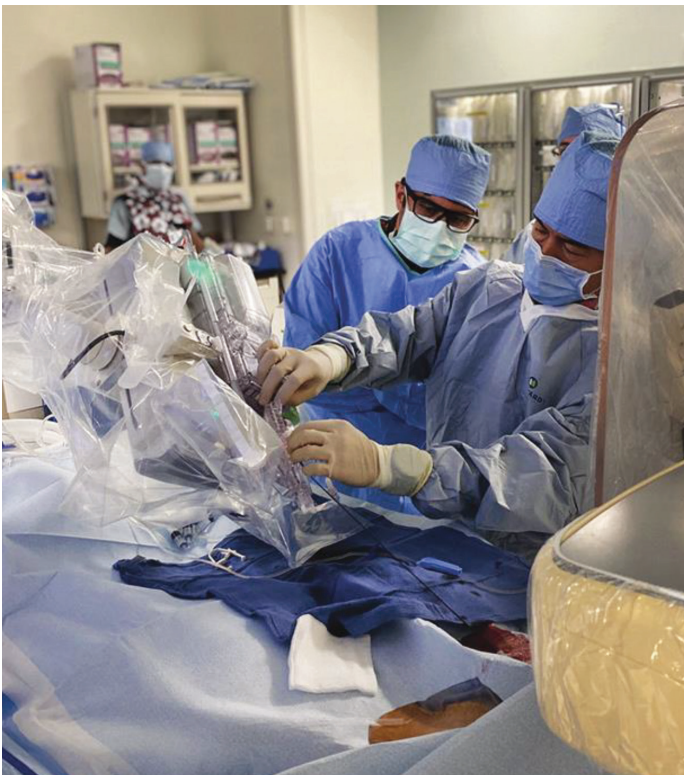Screening for prostate cancer is poised for a significant step forward with MRI imaging to help discriminate when biopsy is called for and when prostate disease should be monitored without invasive testing. “With the introduction of MRI, prostate cancer care has entered a whole new phase where the risk of each individual man is more personalized than it was in the past,” says Dr. Raman. “Based on UCLA research, MRI is the single best marker for predicting clinically significant cancer and also predicting the underlying tumor molecular biology, including hypoxia genes. The combination of artificial intelligence, MRI and PSMA PET scans may be better than any of them alone for diagnosing prostate cancer in the near future.”

# Investigating Robotic Neurointerventions with an Eye Toward Remote Stroke Treatment

**Gary R. Duckwiler, MD**  
Professor and Director Interventional Neuroradiology  
Director, INR Fellowship Program  
Co-Director UCLA HHT Center of Excellence  
Department of Radiological Sciences  
David Geffen School of Medicine at UCLA



The timeliness of treatment plays such a large role in determining outcomes for stroke patients that travel time to an adequately equipped and staffed medical center can become highly problematic, particularly outside of urban centers. Remotely controlled robotic interventions could help reduce the heavy toll exacted each year by delayed stroke treatment, but there is much work to be done in laying the groundwork for this technological solution.



Reprinted with permission of American Society of Neuroradiology, from AJNR, American Journal of Neuroradiology, American Society of Neuroradiology, American Roentgen Ray Society, volume 42, issue 5 2021; permission conveyed through Copyright Clearance Center, Inc.

**Left:** Sterile Corpath GRX patient-side robotic system during setup. **Right:** Lead-shielded remote Corpath GRX control station during cerebral angiography procedure.

Robotic control for neurointerventional procedures can offer advantages over manual control even when there is no need for the procedure to be performed remotely. When operating the controls of a robot, the neurointerventionalist can work from a safe location, away from possible radiation exposure and freed from the need to wear lead protection. Robotic control may even prove to have value for interventional radiologists who are learning procedures that are new to them by providing an enhanced margin of safety in how they manipulate their tools and devices. Researchers are also looking into ways to add a layer of artificial intelligence to help operators navigate complex three-dimensional anatomy and to further enhance the safety and efficiency of using a robot for these procedures.

“The robot may have benefits because of greater fine control over the movement of the devices. Using joystick controls and having geared mechanisms, you can do various incremental movements potentially more accurately than with manual control,” says Gary

Duckwiler, MD, professor of radiology and neurosurgery, and chief and fellowship director of the Division of Interventional Neuroradiology. “But the huge potential for this is in determining if we can do remote work with the robot.”

The robot that is currently available and FDA approved for neurointerventional procedures is being used for diagnostic cerebral angiography and carotid stenting, which can be done utilizing a single catheter. “Driving one catheter up requires a certain number of gears and channels; driving two catheters up requires additional gears and channels,” explains Dr. Duckwiler. “Ultimately, to do a full stroke case will require multiple channels, and that capability is not currently available, though it is under development.”

UCLA currently has the single-catheter robot installed in its clinical angiography suite and has begun using it in patient care. A second, dual-catheter robot will soon be installed in UCLA’s

---

## Robotic control for neurointerventional procedures can offer advantages over manual control even when there is no need for the procedure to be performed remotely.

---


research facility. While this device is not yet FDA approved, it is being used by centers in Canada and France to treat brain aneurysms and will be an important part of investigations being carried out at UCLA to pave the way for robots to be used in remote neurointerventional procedures.

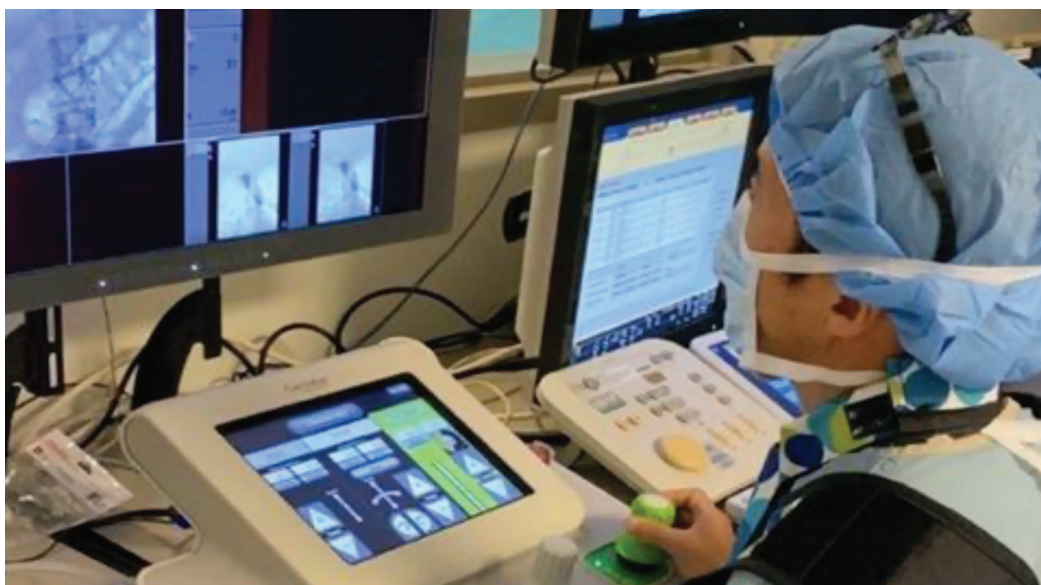Working with other sites in the UC system — UC San Francisco also has a robot in its clinical practice — Dr. Duckwiler and other UCLA neurointerventionalists are delineating the workflow, processes and requirements to enable remote work. “We’re working with our fellow institutions on range-finding for the things that are going to be necessary to do remote procedures,” says Dr. Duckwiler. “Things like: do I wear a headset; how many cameras do I need in the room to see the patient, the groin and the associated staff; how do I control the angio suite and X-ray in that room; how many channels of communication do I need when I operate; what is the time lag; what speed do I need from my internet connection to drive different parts of the procedure. Before we actually put a catheter in a remote patient, all that infrastructure is critical.”

Following this work on the necessary external conditions for remote work, Dr. Duckwiler and his UCLA colleagues will begin pre-clinical work within the institution using the robots in the clinical angiography suite and the research facility. They will then expand their work to include pre-clinical remote work with other institutions. “That will form the baseline for requirements moving forward — hopefully in two years or so — to doing remote diagnostic studies using the current, FDA-approved robots in the clinical setting,” explains Dr. Duckwiler. “I will

have an expert physician at UCSF at the bedside ready to take over at any time, but I would do the angiogram on the UCSF patient from Los Angeles. They would reverse the process and perform a diagnostic angiography procedure on a UCLA patient.” Meanwhile, the more advanced, dual-catheter robot being installed at UCLA’s research facility will be used for pre-clinical investigation of aneurysm interventions, beginning with local robotic control and advancing to remote pre-clinical work.

Another focus of the pre-clinical investigations will be evaluating the group of devices supported by the robot and how that group may need to be expanded to meet the requirements of performing more advanced procedures. “The current generation of robot doesn’t allow for the full range of wires and catheters we would use under manual conditions,” Dr. Duckwiler points out. “If we’re going to be doing more advanced interventions — aneurysms, stroke, embolizations — we need to understand the full range of devices we would need and how the robot would need to be able to incorporate those devices.”

For Dr. Duckwiler, the ultimate goal is to bring critical procedures that re-establish blood flow to stroke victims who don’t have ready access to expert treatment. Many areas, even moderate population centers, aren’t able to support the teams of experts necessary to offer round-the-clock access to stroke interventions. “There are large swaths of the country and large swaths of the world that don’t have that,” says Dr. Duckwiler. “Our motivation is to be able to bring these life-saving treatments to these individuals who would not otherwise have access to timely care.” 



Reproduced from *BMJ Case Reports*, Satoshi Tateshima, Hamidreza Saberi, Geoffrey P Colby, Dieter Enzmann, Gary Duckwiler, volume 14, page 2, copyright 2021 with permission from BMJ Publishing Group Ltd.

Catheter manipulation using a push-pull and rotation joystick control solely based on the visual information.

# Using Artificial Intelligence to Interpret Screening Mammograms

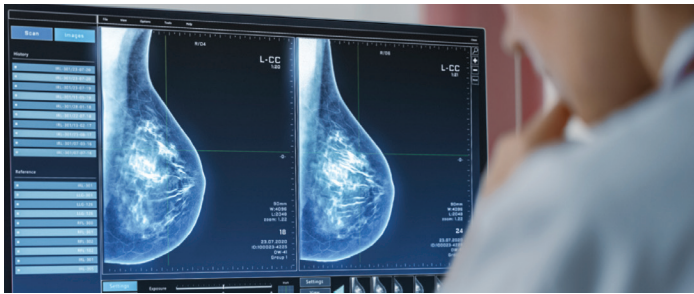


**Cheryce Poon Fischer, MD**  
Professor of Radiology  
Section Chief of Breast Imaging  
Director of Iris Cantor Breast Imaging Center  
Department of Radiological Sciences  
David Geffen School of Medicine at UCLA



**Hannah Milch, MD**  
Assistant Professor of Radiology  
Department of Radiological Sciences  
David Geffen School of Medicine at UCLA

“Screening mammography is the cornerstone of breast cancer detection,” says Cheryce Poon Fischer, MD, professor of radiology, section chief and director of the Iris Cantor Breast Imaging Center. During the 12 months ending in October 2021, over 38 million screening mammograms were performed in the U.S. “The sheer volume of screening mammograms is staggering, requiring a large number of highly subspecialized radiologists for accurate interpretation,” continues Dr. Fischer.



UCLA is currently exploring what role machine learning (ML) and artificial intelligence (AI) can play in managing the high daily workload for radiologists by aiding in the interpretation of screening mammograms. “A reliable AI system could help with workflow by efficiently triaging patients with suspicious findings on screening exams and by helping mammographers reduce callback rates,” explains Dr. Fischer. Decreasing callback rates reduces patient radiation exposure, allays patient anxiety and frees up physician time to increase overall efficiency.

While computer-aided detection (CAD) systems have been under development for decades, the first CAD software was not approved for use by the FDA until 1998. CAD systems are very different from the ML algorithms that are currently generating a great deal of interest in many areas of radiology. While CAD could highlight focal areas of increased breast tissue density and microcalcifications, it has not proved to be impactful in helping radiologists interpret image data or in increasing efficiency.


AI systems for mammography use deep convolutional neural networks that learn how to classify image data. Such systems are able to aid in breast cancer detection in a more nuanced way than could earlier CAD systems by more adeptly handling ambiguous data. Today’s AI systems evaluate mammography images and assign numerical values to indicate the risk of breast cancer. These AI systems provide a score for each finding on a mammogram, calculating the probability of cancerous tissue for each suspicious area of interest.

Dr. Fischer points out that current AI systems are not intended to replace the human radiologist, but to serve as a smart assistant in interpreting screening mammograms. The numerical results of the AI system’s evaluation are available to radiologists in real time as they review images, helping them better and more quickly interpret the entire study.

UCLA is embarking on an extensive and multi-pronged research program to evaluate the performance of AI in assisting the

interpretation of screening mammograms and contributing to the clinical practice of screening mammography, as well as how AI should be practically integrated into the high-volume clinical workflow. The research is starting with a retrospective study testing ML algorithms on 5,000 screening mammograms performed at UCLA from 2010 to 2015. Various competing ML algorithms have been tested by their developers, who have reported their findings and have made claims about their algorithm’s accuracy based on that data. “There is, however, concern that the performance measures of these ML algorithms using the vendors’ test cases may not be fully generalizable to the screening mammograms performed at UCLA,” explains Hannah Milch, MD, assistant professor of radiology, who serves as one of the lead investigators in this research. “There might be differences in patients’ diversity, breast density, medical and surgical history, race, ethnicity and breast cancer risk.” After assessing how the different ML algorithms perform on our own archived data set, UCLA will install one of the systems and perform a prospective clinical trial to fully evaluate how it performs in UCLA’s everyday screening mammography workflow. “While there are some interesting clinical trials coming out of Europe, we’re expecting to be at the forefront of actually using and prospectively studying AI in reading screening mammograms,” explains Dr. Milch.

Drs. Fischer and Milch and their colleagues are also thinking about the practical adoption and future developments needed. “Present AI systems do not look at prior films when they do their interpretation, whereas the human radiologist does,” says Dr. Fischer. “If the AI system could look at prior films and add that information to what it detects in the present films, it will be more useful, more accurate, and more able to diagnose very early stages of cancer by detecting subtle digital imaging changes in the breast tissue that may be difficult for the human eye to perceive.” Other information that could be incorporated to improve future AI systems includes demographics such as patient age, cancer history, genetic information and even social determinants of health.

Foreseeing a day when AI will play an even larger role in triaging screening mammograms, Dr. Fischer notes that many of the breast imaging radiologist’s hours are currently spent assessing healthy women. “With a robust, dependable AI system, we could decrease the time spent on evaluating normals in the daily workload, freeing us to spend more time on complex diagnostic exams, cross sectional MRI exams, biopsies and other interventional procedures — areas where AI cannot replace humans.” 

# Brenda Izzi Recognized for a Whale of a Career

*No cetaceans, but an impressive citation*



**“We are thought leaders in clinical care as well as in research and education and it’s been so amazing to be part of such a dynamic group that cares about being the best.”**

**– Brenda Izzi, RN, MBA**

Brenda Izzi, RN, MBA, senior director of clinical operations in the Department of Radiology, was awarded the Lifetime Achievement Award by the Association of Administrators in Academic Radiology (AAARAD). The honor, which no candidate has been granted since 2014, recognizes an individual with longevity in the field who has made significant contributions to AAARAD, SCARD and the field of academic radiology.

Izzi says “I kind of fell into this whole career. I wanted to be a whale behaviorist.” After her family moved from Hawaii to New Mexico, where “there are no whales and no marine biology degrees, I pivoted to the nursing program to get my LVN.”

She came to UCLA in 2001 to interview for a manager position in radiology at UCLA Medical Center, Santa Monica. Dr. Enzman instead encouraged her to consider the chief administrative officer position, overseeing the education, research and clinical missions of the department. When the CAO role was later split into multiple positions, Izzi took the clinical director role.

We had a chance to ask Izzi some questions about her distinguished UCLA career.

### ***What have you learned in your career and how has it helped you?***

When I started in nursing, I knew I was going to have to develop a really keen sense of understanding people and what motivates them in order to get them to buy into their care plan. It turns out to be a skill set you expand upon as you grow in your leadership role. Learning how to read people, to understand their perspective and try to bring a group to compromise is incredibly useful.

### ***Do you have a guiding principle in your work?***


Doing what you believe to be the right thing without requiring it to always be your way. It shouldn’t be my way, it should be the way that’s best for everybody, the way that’s best for the patient, the way that’s best for the staff, the way that’s best for the organization. Keeping that at the forefront of what you’re doing really helps you make

decisions and allows you to sleep at night even when you have to make a difficult one. That’s because you know you’re doing the right thing by those who rely on you.

### ***What makes you proud about your time at UCLA thus far?***

When I started, the department was relatively small — about 260 people. Now, we have 1,600 to 1,800 working in our department. We have so much depth in the community with our hub imaging centers and the three hospitals. The breadth of quality that we provide is, for me, something to be really proud of. We are thought leaders in clinical care as well as in research and education and it’s been so amazing to be part of such a dynamic group that cares about being the best.

### ***What goal do you still pursue?***

The biggest challenge now is trying to keep this UCLA culture moving forward. We have a deep and rich history from the very beginning; I want to make sure the team always feels connected to that. 

## Photon Counting Detector CT May Offer More Definitive Images in Difficult Cases

**Michael McNitt-Gray, PhD, DABR, FAAPM, FACR**  
 Professor of Radiology  
 Director, Physics and Biology in Medicine Graduate Program  
 Department of Radiological Sciences  
 David Geffen School of Medicine at UCLA



A new development in CT imaging technology has the potential to better discriminate between different tissues being imaged while offering increased spatial resolution. It could prove extremely valuable in the clinical setting, particularly in cases where current CT technology fails to provide definitive images, and could prove to be a significant boon in research applications as well.

Conventional CT detectors — also called energy-integrating detectors — rely on a two-step conversion of incoming X-ray photons to construct images. When X-ray photons reach the detector, they are first converted to photons of visible light in a process called scintillation. These visible light photons then strike the photo diode and are converted to electrical signals. An anti-scatter grid constrains the incoming visible light photons to the areas of the detector that correspond to the locations of the incoming X-ray photons, but decreases the efficiency of the detector. The gridlines don't absorb light photons, so some information is lost.


The new CT technology — called photon-counting detectors or PCD-CT — eliminates the scintillation step, instead directly converting incoming X-ray photons into electrical signals. “You can more accurately locate where the X-ray photon interacts than you could before, and that gives better spatial resolution, which translates to more fine detail in images,” explains Michael McNitt-Gray, PhD, professor of radiology. “You can locate more specifically and accurately where each photon interacts.”

In addition to recording each photon strike without the intermediary of scintillation, the new CT technology records the energy of each X-ray photon. This additional information about the incoming X-ray photons can reveal more information about the tissue through which the photons have passed. By applying different energy thresholds to the resulting image, radiologists will be able to discriminate between different types of tissue —

or tissue and contrast agents — more accurately than conventional CT imaging is able to. “By selecting specific energy thresholds, it's possible to make educated guesses about the kind of tissue the X-ray has passed through,” notes Dr. McNitt-Gray. “For example, the technology can help discriminate between bone and iodine contrast based on how the X-rays are absorbed at different energy thresholds.”

The ability to constrain images by energy threshold also makes it possible to eliminate low-energy noise coming from the detector. Because of its ability to eliminate background noise, PCD-CT may prove more capable than conventional CT systems in low-dose imaging. In these applications, the relatively fewer X-ray photons will not be obscured by detector noise as can be the case with conventional CT. Indications are that the new technology will at worst be radiation-dose neutral.

In addition to its potential for bringing greater clarity to clinical imaging, PCD-CT's richer information yield could prove to be an important new tool for researchers. “The implications for machine learning / AI, for example, are very interesting to contemplate,” says Dr. McNitt-Gray. The additional resolution and energy-level information may result in AI algorithms that are better able to interpret imaging data. “For AI, this represents a change at the front end of the imaging chain. We've been trying to do AI with the same technology for a long time — to be able to add increased information at the very place we interact with the patient, that's pretty exciting.”

The new PCD-CT scanner recently received FDA clearance for clinical use in what they called the “first new major technological improvement for computed tomography imaging in nearly a decade.” UCLA currently intends to acquire a PCD-CT scanner in about a year. Plans are for it to be initially available in one of UCLA Radiology's outpatient clinics. 

## FACULTY AWARDS & RECOGNITIONS



### **Kathleen Ruchalski, MD**

Kathleen Ruchalski, MD, was selected to participate in the 2021-2022 FDA-AACR Oncology Educational Fellowship by the American Association for Cancer Research (AACR). The fellowship focuses on oncology drug development and the regulatory review process.



### **Shabnam Mortazavi, MD**

#### **William Hsu, PhD**


Shabnam Mortazavi, MD, and William Hsu, PhD, received an intramural award from UCLA Jonsson Comprehensive Cancer Center for research focused on mapping breast MR and histopathology in breast conserving surgery.





# UCLA Radiology Alumni Connections

## Chief Residents (2021-2022)



From left: Brian Tsui, Steven Reed Plimpton, Sipan Mathevosian, Shimwoo Lee

### Shimwoo Lee, MD

Shimwoo was born in Seoul, Korea, and moved to Modesto, California in her early teens with her parents and younger sister. She attended Harvard University, majoring in chemical and physical biology with an East Asian studies minor. She received her medical degree from New York University School of Medicine. After completing her internal medicine internship at UCSF Fresno, Shimwoo joined UCLA as an integrated interventional radiology resident. This year, she is honored to serve as one of four radiology chief residents at UCLA. She feels fortunate to have had access to a wealth of excellent clinical and academic opportunities at UCLA and hopes to pay it forward by helping her fellow residents find ways to meet their own educational goals during their training. Her hobbies include digital illustration, cooking Korean food (including making kimchi from scratch), and resistance training.

### Sipan Mathevosian, MD, MS

Sipan is a Southern California native raised in Glendale, California. He attended University of California, Santa Barbara for his undergraduate education where he majored in biopsychology. He then earned a master's in biomedical sciences then completed his medical training at Chicago Medical School, where he was active in curriculum development and interventional radiology research and education. He graduated medical school with distinction and was inducted into the Alpha Omega Alpha honor society. He completed an internship in surgery at Kaiser Permanente LAMC, followed by residency training in diagnostic radiology at UCLA, and is currently training to become a world class vascular interventional radiologist at UCLA. Sipan is deeply honored to accept the role of chief resident and looks forward to working alongside his co-chiefs to promote a wonderful training environment.

### Steven Reed Plimpton, MD, MS

Steven "Reed" Plimpton was born and raised in Phoenix, Arizona, the eldest and least successful of four children. Mistakenly thinking the West had nothing left to offer, he matriculated at the University of Pennsylvania where he studied physics. He also earned his master's in Philly before moving to the University of Colorado to work in radiation oncology. Having decided on yet more schooling, he attended the University of California, Irvine for medical school. He then made the best decision of his life to complete his preliminary year in Portland, Oregon where he met his fiancé, Elle. To continue his trend of sampling Southern California universities and keep his stalwart dog, Samwise, close to his favorite dog beach, he will be a fellow at USC in breast/body. Reed is humbled by having been chosen as a chief resident and will do his best to keep up with his extraordinary co-chiefs.

### Brian Tsui, MD

Brian was born and raised in Fremont, California. After 18 years in Northern California, he decided to move to Southern California to study bioengineering at UCSD, where he graduated summa cum laude. Brian then attended medical school at Case Western Reserve University, where he was inducted into the Alpha Omega Alpha honor society. He decided that he wanted to come back to California after four snowy years and completed an intern year at UC Irvine before starting a residency in diagnostic radiology at UCLA. After finishing residency, he will move back to Northern California for a neuroradiology fellowship at UCSF. Brian is thrilled to work with Reed, Shimwoo, and Sipan as co-chiefs. He is looking forward to supporting radiology residents in the program as they advance through their graduate medical education.

## Chief Fellows (2021-2022)



### Daniel Bradley, MD

Daniel was born and raised in Detroit, Michigan. He decided to escape the cold and completed his undergraduate education at Stanford University. Prior to medical school, Daniel spent some time in Atlanta working in health care consulting. Subsequently, he returned to California to continue his education at the Keck School of Medicine of University of Southern California where he was inducted into the Alpha Omega Alpha honor society. Daniel has enjoyed his radiology residency here at UCLA and is excited to continue his training at UCLA as a breast imaging fellow.



### Alex Chung, MD

Alex was born and raised in Portland, Oregon. He attended Yale University for his undergraduate education where he majored in psychology. Prior to medical school, Alex returned to Portland to work at the Dotter Interventional Institute at Oregon Health & Science University conducting translational research. Medical school took Alex to Atlanta, Georgia, where he finished medical school and internship at Emory University School of Medicine. Alex has enjoyed his residency here at UCLA and is excited to continue his training at UCLA as an abdominal imaging fellow and is up to the challenge of tracking down Dr. Raman.



### Andrew Surman, MD

Andrew was born and raised in Corona, California. He attended California State University, Fullerton for his undergraduate education where he earned a degree in biology. At Cal State Fullerton, he did molecular biology research on Alzheimer disease. Medical school took Andrew to University of California, San Francisco School of Medicine. Following his medical intern year at California Pacific Medical Center, Andrew was excited to return to Los Angeles for residency. Andrew will be continuing at UCLA for a fellowship in musculoskeletal imaging, during which time he is excited to take on the role of co-chief fellow and bring hope to the lives of fellows everywhere.

## End-of-Year Event 2021



Graduating resident class



Diagnostic and interventional radiology residents

## Welcome Reception 2021



First year resident class



Abdominal imaging/CSIR fellows and faculty

## New Faculty

### **Matthias Benz, MD** – Oncology Imaging

Research Fellowship: University of California Los Angeles, Nuclear Medicine  
Residency: University Hospital Basel Switzerland, Nuclear Medicine and Radiology

### **Nina Capiro, MD** – Breast Imaging

Fellowship: UCLA Health, Breast Imaging  
Residency: UCLA Health, Diagnostic Radiology

### **Jena Depetris, MD** – Abdominal Imaging

Fellowship: UCLA Health, Abdominal Imaging and CSIR  
Residency: Massachusetts General Hospital, Diagnostic Radiology

## Residents: Diagnostic Radiology (Class of 2025)

**Joseph Chen, MD** (University of California, Irvine School of Medicine)

**Marie Cumigad, MD** (Chicago Medical School at Rosalind Franklin University of Medicine & Science)

**Vivian Hoang, MD, MPH** (Louisiana State University School of Medicine in New Orleans)

**Ryan Kent, MD, MS** (New York Medical College)

**Dan Li, MD** (David Geffen School of Medicine at UCLA)

**Mark McArthur, MD, MA** (University of Illinois College of Medicine)

**Mariko Nakayama, MD** (Kobe University School of Medicine)

**Allyssa Schik, MD** (University of Minnesota Medical School)

**Margit Szabari, MD, PhD, M.Sc** (University of Szeged Faculty of Medicine)

**Zachary Winchester, MD** (Georgetown University School of Medicine)

## Residents: Interventional Radiology – Integrated (Class of 2026)

**Madhu Joshi, MD** (State University of New York Downstate Medical Center)

**Steven Lee, MD** (University of Illinois College of Medicine)

**Bowen Wei, MD** (David Geffen School of Medicine at UCLA)

## Recent Radiology Events

In June of 2021 the Department of Radiological Sciences hosted the annual End-of-Year Event at the Skirball Cultural Center. This outdoor dinner allowed the department to celebrate the many success of the 2021 academic year as well as honor the outgoing residents and fellows.

In July of 2021, the Department of Radiological Sciences hosted the annual Welcome Reception at the Fowler Museum at UCLA. This outdoor reception allowed for a formal introduction of the new faculty, fellows and residents.

## Stay in Touch!

If you have changed your contact information recently, let us know so we can keep in touch! Are you the recipient of a recent award or distinction? If so, we would like to know about it and post it on our newsletter/alumni web page. Contact Anna White at [avwhite@mednet.ucla.edu](mailto:avwhite@mednet.ucla.edu) or visit us at: <http://radiology.ucla.edu/alumni>

## Fellows 2021-2022

### **Alan Alexander, MD, MS** – Musculoskeletal Imaging

Residency: Georgetown University Hospital, Diagnostic Radiology and Aultman/  
Cleveland Clinic- Mercy/Northeast Ohio Medical University, Diagnostic Radiology

### **Hayet Amalou, MD** – Women's Imaging

Residency: University of California Los Angeles, Diagnostic Radiology

### **Daniel Bradley, MD** – Breast Imaging

Residency: University of California Los Angeles, Diagnostic Radiology

### **Matthew Burr, MD** – Abdominal Imaging

Residency: Virginia Commonwealth University Health System, Diagnostic Radiology

### **Alex Chung, MD** – Abdominal Imaging

Residency: University of California Los Angeles, Diagnostic Radiology

### **Priyanka Dube, DO, MS** – Abdominal Imaging

Residency: The Ohio State University Wexner Medical Center, Diagnostic Radiology

### **Phong Ha, MD** – Neuroradiology

Residency: Cedars Sinai Medical Center, Diagnostic Radiology

### **Jason Hanley, MD** – Independent Interventional Radiology

Residency: University of California Los Angeles, Diagnostic Radiology

### **Frank Hebroni, MD** – Neuroradiology

Residency: University of California Los Angeles, Diagnostic Radiology

### **Amir Imanzadeh, MD** – Cardiothoracic & Abdominal Imaging

Residency: Yale University School of Medicine, Diagnostic Radiology

### **Haddy Jarmakani, DO** – Abdominal Imaging

Residency: Yale University School of Medicine, Diagnostic Radiology

### **Christina Jeong, MD, MS** – Abdominal Imaging

Residency: Dartmouth-Hitchcock Medical Center, Diagnostic Radiology

### **Kenton Kagy, DO** – Breast Imaging

Residency: San Antonio Uniformed Services Health Education Consortium,  
Diagnostic Radiology

### **David Kimball, MD** – Interventional Neuroradiology

Residency: University of Florida, Diagnostic Radiology

### **Michael Jinpyo Lee, MD** – Neuroradiology

Residency: University of Michigan Ann Arbor, Diagnostic Radiology

### **Michael Jung Lee, MD** – Neuroradiology

Residency: University of Southern California, Diagnostic Radiology

### **Olivia Linden, MD** – Breast Imaging

Residency: University of California San Francisco, Diagnostic Radiology and  
Biomedical Imaging

### **Hanna Liu, MD, MBA** – Breast Imaging

Residency: University of California Irvine Medical Center, Diagnostic Radiology

### **Jose Morales, MD, M.Sc** – Interventional Neuroradiology

Residency: Northwestern University McGraw Medical Center, Neurology

### **Sohrab Nazertehrani, MD** – Cardiothoracic Imaging

Residency: Texas Tech University Health Center, Categorical Diagnostic  
Radiology and Albany Medical Center, Categorical Diagnostic Radiology

### **Emilie Nguyen, MD** – Abdominal Imaging

Residency: Kaiser Permanente Los Angeles, Diagnostic Imaging

### **Andrew Ong, MD** – Neuroradiology

Residency: Johns Hopkins University School of Medicine, Diagnostic Radiology

### **Richard Rothman, MD** – Abdominal Imaging

Residency: Yale University School of Medicine, Diagnostic Radiology

### **Hamidreza Saber, MD, MPH** – Interventional Neuroradiology

Residency: Wayne State University, Neurology

### **Andrew Surman, MD** – Musculoskeletal Imaging

Residency: University of California Los Angeles, Diagnostic Radiology

### **Pejman Taghavi, MD** – Musculoskeletal Imaging

Residency: John H. Stroger Hospital of Cook County, Diagnostic Radiology

### **Willy Tjong, MD** – Neuroradiology

Residency: University of Rochester Medical Center, Diagnostic Radiology

### **Eva Xia, MD** – Abdominal Imaging

Residency: Albert Einstein Medical Center, Diagnostic Radiology

### **David Zucker, MD, M.Sc** – Independent Interventional Radiology

Residency: University of California Los Angeles, Diagnostic Radiology

405 Hilgard Avenue  
Los Angeles, CA 90095

NONPROFIT  
ORGANIZATION  
U.S. POSTAGE

**PAID**

UCLA



You have the power to make a world of difference in radiological sciences. Join forces with UCLA to advance human health and improve outcomes and quality of life for patients and their loved ones. If you would like information on how you can help, please contact:

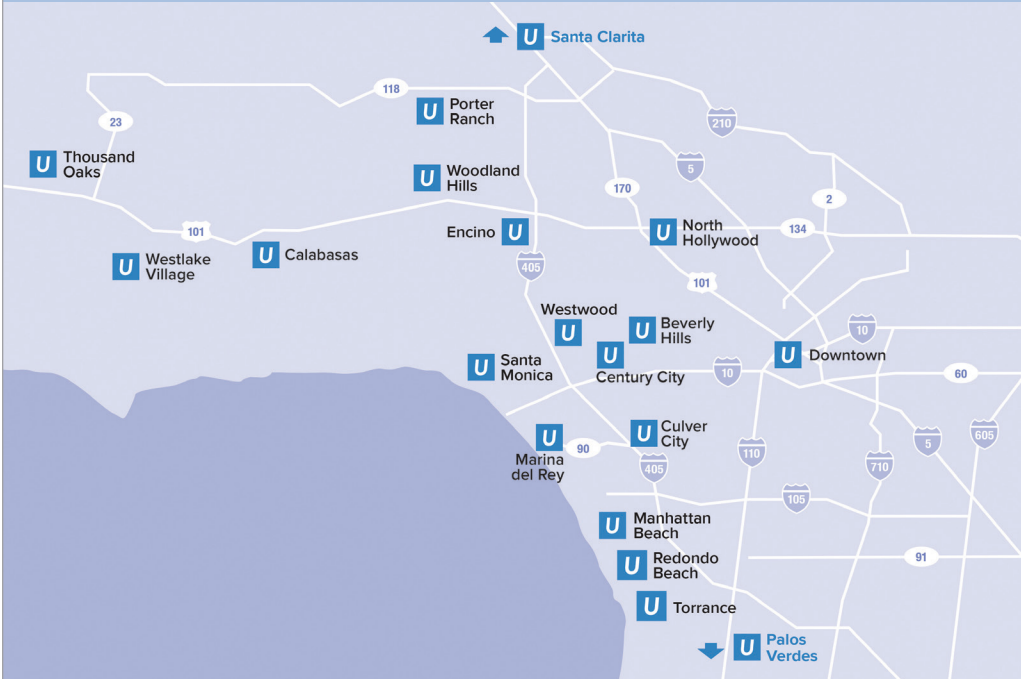Gemma Badini  
Senior Director of Development, UCLA Health Sciences  
**310-206-9235**  
[GBadini@mednet.ucla.edu](mailto:GBadini@mednet.ucla.edu)  
or go to: [www.uclahealth.org/radiology/giving](http://www.uclahealth.org/radiology/giving)



**#1 in California**  
and top 3 in the nation –  
our ranking gives you and  
your family the confidence  
you need.

## Our locations

UCLA Radiology is committed to providing outstanding patient care through excellence in clinical imaging at a number of convenient locations.  
For more information, visit [www.uclahealth.org/radiology](http://www.uclahealth.org/radiology) or call **(310) 301-6800**.



### Radiology

WINTER 2021

**LEO G. RIGLER CHAIR AND PROFESSOR**  
Dieter R. Enzmann, MD

**EXECUTIVE VICE CHAIR**  
Jonathan G. Goldin, MD, PhD

**SENIOR DIRECTOR, CLINICAL OPERATIONS**  
Brenda Izzi, RN, MBA

**CHIEF ADMINISTRATIVE OFFICER**  
Suzie Morrel, MSF

**BUSINESS DEVELOPMENT**  
Leila Farzami

**WRITER**  
David Barrad

**DESIGN**  
SD Graphics



Contact us at:  
**[RadNewsletter@mednet.ucla.edu](mailto:RadNewsletter@mednet.ucla.edu)**

A Publication of  
UCLA Department of Radiological Sciences  
©2021 UCLA Radiology Department All rights reserved